Breathlessness

START HERE

ASSESS
ABCDE, observations. Oxygen if hypoxic.

CONFIRM FLUID
Exam, CXR and thoracic ultrasound.

SIDEDNESS
Bilateral or unilateral?

CHECK FOR HF
JVP, oedema, orthopnoea and crackles.

ESCALATE
Sepsis, hypoxia or severe work of breathing.

Pleural fluid is a clue. Treat the cause, not just the X-ray.

PLEURAL EFFUSIONS AT A GLANCE

1 BILATERAL EFFUSIONS

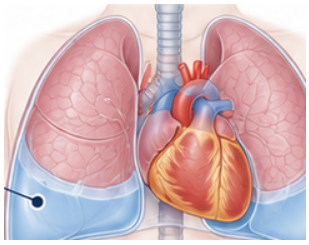

CLUES TO FLUID OVERLOAD

- Orthopnoea, peripheral oedema and raised JVP
- Reduced breath sounds at both lung bases
- Heart failure is common, but bilateral fluid is not diagnostic

CONFIRM ACUTE HEART FAILURE

- Clinical exam, ECG, CXR, FBC and renal bloods
- In NEW suspected acute HF, BNP <100 or NT-proBNP <300 ng/L makes HF less likely
- Raised peptides or new HF: request echo; consider within 48 h if admitted

TREAT THE FLUID OVERLOAD

- Sit upright. Give oxygen if hypoxic
- IV loop diuretic (e.g. furosemide)
- Monitor urine output, U&Es, creatinine and daily weight
- Involve the specialist heart-failure team

DOES IT NEED DRAINING?

- Usually treat obvious heart failure first
- Seek pleural review if large, atypical or not improving

Bilateral + overloaded? Treat HF first.

2 UNILATERAL EFFUSION

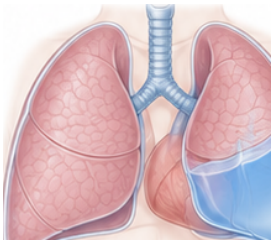

DIFFERENTIAL DIAGNOSES

- Malignancy or pleural infection / empyema
- Pulmonary embolism or tuberculosis
- Heart failure can also be unilateral

CLUES FROM THE HISTORY

- Fever or pleurisy: infection or PE
- Weight loss / trauma: cancer or bleeding

HOW TO INVESTIGATE

- CXR and thoracic ultrasound
- Ultrasound-guided aspiration if unexplained
- Send protein, LDH, culture, cytology; pH if infection
- Consider CT and respiratory referral

ACT URGENTLY IF

- Empyema / sepsis or marked hypoxia
- Cancer suspicion: prompt referral pathway

Unilateral? Keep a broad differential.

REMEMBER

Treat the cause
Pleural fluid may be a clue, not the sole problem.

Ultrasound matters
Use imaging to plan any pleural procedure.

Ask for help
Escalate infection, hypoxia or uncertain causes.

NICE acute HF BTS pleural guidance